



Protocol for the Examination of Resection Specimens From Patients With Carcinoma of the Ureter and Renal Pelvis

Version: 2.2.0.0

Protocol Posting Date: June 2021

CAP Laboratory Accreditation Program Protocol Required Use Date: March 2022

The changes included in this current protocol version affect accreditation requirements. The new deadline for implementing this protocol version is reflected in the above accreditation date.

For accreditation purposes, this protocol should be used for the following procedures AND tumor types:

Procedure	Description
Ureterectomy	Includes specimens designated ureterectomy and nephroureterectomy
Tumor Type	Description
Carcinomas	Includes invasive carcinomas of the urinary tract, including urothelial carcinoma and its morphological variants (squamous cell carcinoma, adenocarcinoma, Müllerian carcinoma, neuroendocrine carcinoma, and sarcomatoid carcinoma)#

This protocol is recommended for reporting noninvasive urothelial tumors (papillary and flat), but it is not required for accreditation purposes.

This protocol is NOT required for accreditation purposes for the following:

Procedure
Biopsy (consider the Ureter and Renal Pelvis Biopsy protocol)
Primary resection specimen with no residual cancer (eg, following neoadjuvant therapy)
Cytologic specimens

The following tumor types should NOT be reported using this protocol:

Tumor Type
Lymphoma (consider the Hodgkin or non-Hodgkin Lymphoma protocols)
Sarcoma (consider the Soft Tissue protocol)

Authors

Gladell P. Paner, MD*; Peter A. Humphrey, MD, PhD*; Ming Zhou, MD, PhD*; Lara R. Harik, MD; Robert Allan, MD; Mahul B. Amin, MD; Anthony Chang, MD; Arthur H. Cohen, MD; Brett Delahunt, MD; Jonathan I. Epstein, MD; David J. Grignon, MD; Rodolfo Montironi, MD; Jason Pettus, MD; Victor E. Reuter, MD; John R. Srigley, MD.

With guidance from the CAP Cancer and CAP Pathology Electronic Reporting Committees.

* Denotes primary author.

Accreditation Requirements

This protocol can be utilized for a variety of procedures and tumor types for clinical care purposes. For accreditation purposes, only the definitive primary cancer resection specimen is required to have the core and conditional data elements reported in a synoptic format.

- Core data elements are required in reports to adequately describe appropriate malignancies. For accreditation purposes, essential data elements must be reported in all instances, even if the response is “not applicable” or “cannot be determined.”
- Conditional data elements are only required to be reported if applicable as delineated in the protocol. For instance, the total number of lymph nodes examined must be reported, but only if nodes are present in the specimen.
- Optional data elements are identified with “+” and although not required for CAP accreditation purposes, may be considered for reporting as determined by local practice standards.

The use of this protocol is not required for recurrent tumors or for metastatic tumors that are resected at a different time than the primary tumor. Use of this protocol is also not required for pathology reviews performed at a second institution (ie, secondary consultation, second opinion, or review of outside case at second institution).

Synoptic Reporting

All core and conditionally required data elements outlined on the surgical case summary from this cancer protocol must be displayed in synoptic report format. Synoptic format is defined as:

- Data element: followed by its answer (response), outline format without the paired Data element: Response format is NOT considered synoptic.
- The data element should be represented in the report as it is listed in the case summary. The response for any data element may be modified from those listed in the case summary, including “Cannot be determined” if appropriate.
- Each diagnostic parameter pair (Data element: Response) is listed on a separate line or in a tabular format to achieve visual separation. The following exceptions are allowed to be listed on one line:
 - Anatomic site or specimen, laterality, and procedure
 - Pathologic Stage Classification (pTNM) elements
 - Negative margins, as long as all negative margins are specifically enumerated where applicable
- The synoptic portion of the report can appear in the diagnosis section of the pathology report, at the end of the report or in a separate section, but all Data element: Responses must be listed together in one location

Organizations and pathologists may choose to list the required elements in any order, use additional methods in order to enhance or achieve visual separation, or add optional items within the synoptic report. The report may have required elements in a summary format elsewhere in the report IN ADDITION TO but not as replacement for the synoptic report ie, all required elements must be in the synoptic portion of the report in the format defined above.

Summary of Changes

v 2.2.0.0

- General Reformatting
- Revised Margins Section
- Revised Lymph Nodes Section
- Added Distant Metastasis Section
- Removed pTX and pNX Staging Classification

Reporting Template

Protocol Posting Date: June 2021

Select a single response unless otherwise indicated.

CASE SUMMARY: (RENAL PELVIS AND URETER: Resection)

Standard(s): AJCC-UICC 8

SPECIMEN (Note [A](#))

Procedure

- Nephroureterectomy
 Ureterectomy
 Other (specify): _____
 Not specified

Specimen Laterality

- Right
 Left
 Not specified

TUMOR

Tumor Site (select all that apply)

- Ureter: _____
 Renal pelvis: _____
 Kidney: _____
 Cannot be determined: _____

+Tumor Size

- Greatest dimension in Centimeters (cm): _____ cm
 +Additional Dimension in Centimeters (cm): ____ x ____ cm
 Cannot be determined (explain): _____

Histologic Type (Note [B](#)) (select all that apply)

Urothelial

- Papillary urothelial carcinoma, noninvasive
 Papillary urothelial carcinoma, invasive
 Urothelial carcinoma in situ
 Urothelial carcinoma, invasive
 Urothelial carcinoma, nested (including large nested) variant
 Urothelial carcinoma, microcystic variant
 Urothelial carcinoma, micropapillary variant
 Urothelial carcinoma, lymphoepithelioma-like variant
 Urothelial carcinoma, plasmacytoid / signet ring / diffuse variant
 Urothelial carcinoma, sarcomatoid variant
 Urothelial carcinoma, giant cell variant
 Urothelial carcinoma, poorly differentiated variant
 Urothelial carcinoma, lipid-rich variant
 Urothelial carcinoma, clear cell variant

___ Urothelial carcinoma with squamous differentiation

+Percentage of Squamous Differentiation

___ Specify percentage: _____ %

___ Other (specify): _____

___ Cannot be determined

___ Urothelial carcinoma with glandular differentiation

+Percentage of Glandular Differentiation

___ Specify percentage: _____ %

___ Other (specify): _____

___ Cannot be determined

___ Urothelial carcinoma with trophoblastic differentiation

+Percentage of Trophoblastic Differentiation

___ Specify percentage: _____ %

___ Other (specify): _____

___ Cannot be determined

___ Urothelial carcinoma with Müllerian differentiation

+Percentage of Müllerian Differentiation

___ Specify percentage: _____ %

___ Other (specify): _____

___ Cannot be determined

Squamous

___ Squamous cell carcinoma

___ Verrucous carcinoma

___ Squamous cell carcinoma in situ (no invasive carcinoma identified)

Glandular

___ Adenocarcinoma

___ Adenocarcinoma, enteric

___ Adenocarcinoma, mucinous

___ Adenocarcinoma, mixed

___ Adenocarcinoma in situ (no invasive carcinoma identified)

Tumors of Müllerian Type

___ Clear cell carcinoma

___ Endometrioid carcinoma

Neuroendocrine Tumors

___ Small cell neuroendocrine carcinoma

+Percentage of Small Cell Neuroendocrine Component

___ Specify percentage: _____ %

___ Other (specify): _____

___ Cannot be determined

___ Large cell neuroendocrine carcinoma

+Percentage of Large Cell Neuroendocrine Component

___ Specify percentage: _____ %

___ Other (specify): _____

___ Cannot be determined

___ Well-differentiated neuroendocrine carcinoma

+Percentage of Well-differentiated Neuroendocrine Component

___ Specify percentage: _____ %

___ Other (specify): _____

___ Cannot be determined

___ Other histologic type not listed (specify): _____

+Histologic Type Comment: _____

Histologic Grade (Note C)*For urothelial carcinoma, other variants, or divergent differentiation* Low-grade High-grade*For squamous cell carcinoma or adenocarcinoma* G1, well-differentiated G2, moderately differentiated G3, poorly differentiated GX, cannot be assessed: _____*Other* Other (specify): _____ Cannot be assessed: _____ Not applicable: _____**Tumor Extent (Note D)** Noninvasive papillary carcinoma Carcinoma in situ Invades subepithelial connective tissue Invades muscularis Invades beyond muscularis into periureteral fat or peripelvic fat or renal parenchyma Invades adjacent organs or through the kidney into perinephric fat: _____ Cannot be determined: _____ No evidence of primary tumor**+Lymphovascular Invasion (Note E)** Not identified Present Cannot be determined: _____**+Tumor Configuration (select all that apply)** Papillary Solid / nodule Flat Ulcerated Other (specify): _____ Cannot be determined: _____**+Tumor Comment:** _____**MARGINS (Note F)****Margin Status for Invasive Carcinoma** All margins negative for invasive carcinoma**+Closest Margin(s) to Invasive Carcinoma (select all that apply)** Proximal ureteral: _____ Distal ureteral: _____ Bladder cuff: _____ Deep soft tissue: _____ Other (specify): _____ Cannot be determined (explain): _____

+Distance from Invasive Carcinoma to Closest Margin

Specify in Millimeters (mm)

Exact distance: _____ mm

Other (specify): _____

Cannot be determined

Invasive carcinoma present at margin

Margin(s) Involved by Invasive Carcinoma (select all that apply)

Proximal ureteral: _____

Distal ureteral: _____

Deep soft tissue: _____

Other (specify): _____

Cannot be determined (explain): _____

Other (specify): _____

Cannot be determined (explain): _____

Not applicable

Margin Status for Carcinoma in Situ / Noninvasive Papillary Urothelial Carcinoma

All margins negative for carcinoma in situ / noninvasive papillary urothelial carcinoma

+Closest Margin(s) to Carcinoma in Situ / Noninvasive Papillary Urothelial Carcinoma (select all that apply)

Proximal ureteral: _____

Distal ureteral: _____

Bladder cuff: _____

Other (specify): _____

Cannot be determined (explain): _____

Noninvasive low-grade papillary urothelial carcinoma present at margin

Margin(s) Involved by Low-grade Papillary Urothelial Carcinoma (select all that apply)

Proximal ureteral: _____

Distal ureteral: _____

Bladder cuff mucosal: _____

Other (specify): _____

Cannot be determined (explain): _____

Carcinoma in situ / noninvasive high-grade papillary urothelial carcinoma present at margin

Margin(s) Involved by Carcinoma in Situ / Noninvasive Papillary Urothelial Carcinoma (select all that apply)

Proximal ureteral: _____

Distal ureteral: _____

Bladder cuff mucosal: _____

Other (specify): _____

Cannot be determined (explain): _____

Other (specify): _____

Cannot be determined (explain): _____

Not applicable

+Margin Comment: _____

REGIONAL LYMPH NODES (Note G)

Regional Lymph Node Status

- Not applicable (no regional lymph nodes submitted or found)
- Regional lymph nodes present
 - All regional lymph nodes negative for tumor
 - Tumor present in regional lymph node(s)

Number of Lymph Nodes with Tumor

- Exact number (specify): _____
- At least (specify): _____
- Other (specify): _____
- Cannot be determined (explain): _____

Size of Largest Nodal Metastatic Deposit

Specify in Centimeters (cm)

- Exact size: _____ cm
- At least: _____ cm
- Greater than: _____ cm
- Less than: _____ cm
- Other (specify): _____
- Cannot be determined (explain): _____

+Nodal Site with Largest Metastatic Deposit (specify site): _____

+Size of Largest Lymph Node with Tumor

Specify in Centimeters (cm)

- Exact size: _____ cm
- At least: _____ cm
- Greater than: _____ cm
- Less than: _____ cm
- Other (specify): _____
- Cannot be determined (explain): _____

+Largest Lymph Node with Tumor (specify site): _____

+Extranodal Extension (ENE)

- Not identified
- Present
- Cannot be determined: _____
- Other (specify): _____
- Cannot be determined (explain): _____

Number of Lymph Nodes Examined

- Exact number (specify): _____
- At least (specify): _____
- Other (specify): _____
- Cannot be determined (explain): _____

+Regional Lymph Node Comment: _____

DISTANT METASTASIS**Distant Site(s) Involved, if applicable**

- Not applicable
 Specify site(s): _____
 Cannot be determined

PATHOLOGIC STAGE CLASSIFICATION (pTNM, AJCC 8th Edition) (Note H)

Reporting of pT, pN, and (when applicable) pM categories is based on information available to the pathologist at the time the report is issued. As per the AJCC (Chapter 1, 8th Ed.) it is the managing physician's responsibility to establish the final pathologic stage based upon all pertinent information, including but potentially not limited to this pathology report.

TNM Descriptors (select all that apply)

- Not applicable: _____
 m (multiple)
 r (recurrent)
 y (post-treatment)

pT Category

- pT not assigned (cannot be determined based on available pathological information)
 pT0: No evidence of primary tumor
 pTa: Papillary noninvasive carcinoma
 pTis: Carcinoma in situ
 pT1: Tumor invades subepithelial connective tissue
 pT2: Tumor invades the muscularis
 pT3: For renal pelvis only-Tumor invades beyond muscularis into peripelvic fat or into the renal parenchyma or For ureter only-Tumor invades beyond muscularis into periureteric fat
 pT4: Tumor invades adjacent organs, or through the kidney into the perinephric fat

pN Category

- pN not assigned (no nodes submitted or found)
 pN not assigned (cannot be determined based on available pathological information)
 pN0: No regional lymph node metastasis
 pN1: Metastasis less than or equal to 2 cm in greatest dimension, in a single lymph node
 pN2: Metastasis greater than 2 cm, in a single lymph node; or multiple lymph nodes

pM Category (required only if confirmed pathologically)

- Not applicable - pM cannot be determined from the submitted specimen(s)
 pM1: Distant metastasis

ADDITIONAL FINDINGS**+Associated Epithelial Lesions (Note C) (select all that apply)**

- None identified
 Urothelial papilloma
 Urothelial papilloma, inverted type
 Papillary urothelial neoplasm, low malignant potential (PUNLMP)
 Urothelial proliferation of uncertain malignant potential
 Urothelial dysplasia
 Other (specify): _____
 Cannot be determined: _____

+Additional Findings (select all that apply)

- Inflammation / regenerative changes
- Therapy-related changes (specify): _____
- Cautery artifact
- Cystitis cystica et glandularis
- Keratinizing squamous metaplasia
- Intestinal metaplasia
- Other (specify): _____

Pathologic Findings in Ipsilateral Nonneoplastic Renal Tissue (Note 1) (select all that apply)

- No or insufficient renal parenchyma
- None identified
- Glomerular disease (specify type): _____
- Tubulointerstitial disease (specify type): _____
- Vascular disease (specify type): _____
- Inflammation (specify type): _____
- Other (specify): _____

COMMENTS

Comment(s): _____

Explanatory Notes

A. Procedure

A relevant history is important for interpretation of all upper urinary tract (renal pelvis and ureter) specimens. A history of renal stones, recent urinary tract procedures, infections, or obstruction can influence the interpretation of random biopsies obtained from patients with hematuria. Any neoplasms previously diagnosed should be specified, including the histologic type, primary site, and histologic grade. Primary tumors may be associated with hereditary nonpolyposis colon cancer (HNPCC) syndrome (Lynch syndrome II). Renal pelvic tumors are more often seen in analgesic abusers, who often have analgesic nephropathy, including papillary necrosis. If prior therapy has been given, it should be described (systemic or intravesical chemotherapy, immunotherapy, radiation, etc). The method of collection and date also should be specified in urine cytology specimens. Cytologic specimens from the ureter or renal pelvis may be over-interpreted if their site of sampling is not stated.

Sections for Microscopic Evaluation

Segmental ureterectomy is performed for tumors of the proximal or mid ureter. The length and diameter of the intact ureter is recorded, with a search for a mass by palpation and visual inspection. Proximal and distal cross-section margins are taken, and the outer aspect of the ureter is inked. The ureter is then opened longitudinally and assessed for mucosal abnormalities. After fixation in 10% formalin, sections are taken to demonstrate the deepest invasion of any lesion(s). At least one section of uninvolved ureter should be submitted.

Radical nephroureterectomy with bladder cuff

Gross examination and sampling should document the relationship of tumor to adjacent renal parenchyma, peripelvic fat, nearest soft tissue margin, and ureter. Sections of grossly unremarkable kidney, pelvis, and ureter should be obtained. The important urothelial margin is the urinary bladder cuff, which can be sampled as shave sections.

B. Histologic Type

Like the urinary bladder, the vast majority (more than 95%) of carcinomas of the renal pelvis and ureter are urothelial in origin.^{1,2,3,4,5,6,7} The most recent 2016 World Health Organization (WHO) classification of tumors of the urothelial tract, including urethra, urinary bladder, ureter, and renal pelvis, is provided in this note. Benign tumors are included in this classification because, within the same patient, a spectrum of differentiation from benign to malignant tumors may be seen, either at the same time or over the clinical course of the disease. The full spectrum of invasive urothelial carcinoma and its variants as found in the urinary bladder may also be found in the upper tract. The distinction between a urothelial carcinoma with divergent squamous, glandular, or Müllerian differentiation, and a pure squamous cell carcinoma, adenocarcinoma or Müllerian is rather arbitrary. Most authorities, including the 2016 WHO classification, require a pure histology of squamous cell carcinoma, adenocarcinoma or Müllerian to designate a tumor as such, all others with recognizable papillary, invasive, or flat carcinoma in situ (CIS) urothelial component being considered as urothelial carcinoma with divergent differentiation. A malignant neoplasm with small cell neuroendocrine carcinoma component arising in the urinary tract is designated as small cell carcinoma.

Lynch syndrome, also known as hereditary nonpolyposis colorectal cancer, predisposes patients to urological cancer, particularly upper tract urothelial carcinoma. Upper tract urothelial carcinoma develops in up to 28% of patients with known Lynch syndrome. Therefore, pathologists should be aware of Lynch syndrome and their important role of identifying Lynch syndrome patients by considering appropriate tissue tests. Recently several guidelines have been published regarding when and what tissue testing is appropriate for screening patients with upper tract urothelial carcinoma.^{8,9}

2016 WHO Classification of Tumors of the Urothelial Tract

Urothelial tumors

Infiltrating urothelial carcinoma

- Nested, including large nested
- Microcystic
- Micropapillary
- Lymphoepithelioma-like
- Plasmacytoid/signet ring cell/diffuse
- Sarcomatoid
- Giant cell
- Poorly differentiated

Noninvasive urothelial lesions

- Urothelial carcinoma in situ
- Noninvasive papillary urothelial carcinoma, low grade
- Noninvasive papillary urothelial carcinoma, high grade
- Papillary urothelial neoplasm of low malignant potential
- Urothelial papilloma
- Inverted urothelial papilloma
- Urothelial proliferation of uncertain malignant potential
- Urothelial dysplasia

Squamous cell neoplasms

- Squamous cell carcinoma
- Verrucous carcinoma
- Squamous cell papilloma

Glandular neoplasms

Adenocarcinoma, NOS

Enteric

Mucinous

Mixed

Villous adenoma

Tumors of Müllerian type

Clear cell carcinoma

Endometrioid carcinoma

Neuroendocrine tumors

Small cell neuroendocrine carcinoma

Large cell neuroendocrine carcinoma

Well-differentiated neuroendocrine tumor

Paraganglioma

References

1. Delahunt B, Amin MB, Hofstader F, Hartmann A, Tyczynski JE. Tumours of the renal pelvis and ureter. In: Eble JN, Sauter G, Epstein JI, Sesterhenn IA, eds. *World Health Organization Classification of Tumours: Pathology and Genetics of Tumours of the Urinary System and Male Genital Organs*. Lyon, France: IARC Press; 2004:150-153.
2. Murphy WM, Grignon DJ, Perlman EJ. Tumors of the ureters and renal pelvises. In: *Tumors of the Kidney, Bladder, and Related Urinary Structures. AFIP Atlas of Tumor Pathology. Series 4*. Washington, DC: American Registry of Pathology; 2004:375-379.
3. Moch H, Humphrey PA, Ulbright TM, Reuter VE. *WHO Classification of Tumours of the Urinary System and Male Genital Organs*. Geneva, Switzerland: WHO Press; 2016.
4. Olgac S, Mazumdar M, Dalbagni G, Reuter VE. Urothelial carcinoma of the renal pelvis: a clinicopathologic study of 130 cases. *Am J Surg Pathol*. 2004; 28:1545-1552.
5. Murphy WM. Diseases of the urinary bladder, urethra, ureters and renal pelvis. In: Murphy WM, ed. *Urological Pathology*. 2nd ed. Philadelphia, PA: WB Saunders Co; 1997:75-96.
6. Reuter VE. The urothelial tract: renal pelvis, ureter, urinary bladder, and urethra. In: Mills SE, Carter D, Greenson JK, Oberman HR, Reuter VE, Stoler MH, eds. *Diagnostic Surgical Pathology*. 4th ed. Philadelphia, PA: Lippincott Williams and Wilkins; 2004:2035-2081.
7. Perez-Montiel D, Wakely PE, Hes O, Michal M, Suster S. High-grade urothelial carcinoma of the renal pelvis: clinicopathologic study of 108 cases with emphasis on unusual morphologic variants. *Mod Pathol*. 2006;19:494-503.
8. Mork M, Hubosky SG, Rouprêt M, et al. Lynch syndrome: a primer for urologists and panel recommendations. *J Urol*. 2015;194(1):21-29.
9. Rouprêt M, Babjuk M, Compérat E, et al. European Association of Urology Guidelines on Upper Urinary Tract Urothelial Cell Carcinoma: 2015 update. *Eur Urol*. 2015;68(5):868-879.

C. Histologic Grade

The grading system is identical to that for urinary bladder neoplasms. Flat intraepithelial lesions and papillary and invasive lesions are graded separately. There has been significant controversy in the classification of these lesions.¹ Due to variable classification systems and the need for a universally acceptable system, the World Health Organization/International Society of Urological Pathology (WHO/ISUP) consensus classification was proposed.² This system is utilized in the WHO 2004 classification,³ the 2004 Armed Forces Institute of Pathology (AFIP) fascicle,⁴ and 2016 WHO classification,⁵ and has been validated by many studies to be prognostically significant. Other systems (that were being used previously) may still be used according to institutional preference. Urothelial carcinomas of the renal pelvis tend to more often be high grade^{6,7} compared to urinary bladder carcinomas.

Flat and papillary urothelial hyperplasia has been renamed as “urothelial proliferation of uncertain malignant potential” in 2016 WHO classification.

Squamous carcinomas and adenocarcinomas may be graded as well differentiated, moderately differentiated, and poorly differentiated.

References

1. Amin MB, Murphy WM, Reuter VE, et al. Controversies in the pathology of transitional cell carcinoma of the urinary bladder. In: Rosen PP, Fechner RE, eds. *Reviews of Pathology*. Vol. 1. Chicago, IL: ASCP Press; 1996:1-39.
2. Murphy WM, Grignon DJ, Perleman EJ. Tumors of the ureters and renal pelvis. In: *Tumors of the Kidney, Bladder, and Related Urinary Structures. AFIP Atlas of Tumor Pathology. Series 4*. Washington, DC: American Registry of Pathology; 2004:375-379.
3. Epstein JI, Amin MB, Reuter VR, Mostofi FK, the Bladder Consensus Conference Committee. The World Health Organization/International Society of Urological Pathology Consensus classification of urothelial (transitional cell) neoplasms of the urinary bladder. *Am J Surg Pathol*. 1998;22:1435-1448.
4. Delahunt B, Amin MB, Hofstadter F, Hartmann A, Tyczynski JE. Tumours of the renal pelvis and ureter. In: Eble JN, Sauter G, Epstein JI, Sesterhenn IA, eds. *World Health Organization Classification of Tumours: Pathology and Genetics of Tumours of the Urinary System and Male Genital Organs*. Lyon, France: IARC Press; 2004:150-153.
5. Moch H, Humphrey PA, Ulbright TM, Reuter VE. *WHO Classification of Tumours of the Urinary System and Male Genital Organs*. Geneva, Switzerland: WHO Press; 2016.
6. Olgac S, Mazumdar M, Dalbagni G, Reuter VE. Urothelial carcinoma of the renal pelvis: a clinicopathologic study of 130 cases. *Am J Surg Pathol*. 2004; 28:1545-1552.
7. Margulis V, Shariat SF, Matin SF, et al. Outcomes of radical nephroureterectomy: a series from the Upper Tract Urothelial Carcinoma Collaboration. *Cancer*. 2009;115(6):1224-1233.

D. Extent of Invasion

Depth of invasion and pathologic stage are the most important prognostic indicators for patients with neoplasms of the upper urinary tract.^{1,2} A critical role of the surgical pathologist is to diagnose the depth and extent of invasion into the subepithelial connective tissue/lamina propria (pT1), muscularis propria (pT2), or beyond (pT3 or pT4). The patterns of invasion are similar to the urinary bladder, except that for renal pelvis carcinoma, the type of tumor involvement of the kidney, when present, impacts stage. Also, it is important to note that the lamina propria is absent beneath the urothelium lining the renal papillae in the pelvis and is thin along the minor calyces.³ As in the urinary bladder, in papillary tumors, invasion occurs most often at the base of the tumor and very infrequently in the stalk. Tumor infiltrating the lamina propria is pT1, and, like the urinary bladder, there is no accepted approach for assessing depth of lamina propria invasion. However, pathologists are encouraged to provide some assessment as to the extent of lamina propria invasion (ie, focal versus extensive, or depth in millimeters, or by level – above, at, or below

muscularis mucosae). Designation of a tumor as merely muscle-invasive is inappropriate, but the type of muscle invasion, ie, muscularis mucosae (pT1 tumors) versus muscularis propria (pT2 tumors) invasion, needs to be clearly stated. Descriptive terminology, such as “urothelial carcinoma with muscle invasion, indeterminate for type of muscle invasion,” may be used when it is not possible to be certain whether the type of muscle invaded by the tumor is hypertrophic muscularis mucosae or muscularis propria. For renal pelvic tumors, in-situ extension of carcinoma into renal collecting ducts and renal tubules does not affect stage, while carcinoma invading into the renal parenchyma is pT3. Renal pelvic carcinoma that invades through the kidney into perinephric fat is pT4. Patients with upper tract urothelial carcinoma often present at higher stage compared to patients with urinary bladder carcinoma.^{4,5}

References

1. Gupta R, Paner GP, Amin MB. Neoplasms of the upper urinary tract: a review with focus on urothelial carcinoma of the pelvicalyceal system and aspects related to its diagnosis and reporting. *Adv Anat Pathol*. 2008;15(3):127-139.
2. Margulis V, Shariat SF, Matin SF, et al. Outcomes of radical nephroureterectomy: a series from the Upper Tract Urothelial Carcinoma Collaboration. *Cancer*. 2009;115(6):1224-1233.
3. Reuter VE. Urinary bladder, ureter, and renal pelvis. In: Mills SE, ed. *Histology for Pathologists*. 3rd ed. Philadelphia, PA: Lippincott Williams and Wilkins; 2007:909-922.
4. Olgac S, Mazumdar M, Dalbagni G, Reuter VE. Urothelial carcinoma of the renal pelvis: a clinicopathologic study of 130 cases. *Am J Surg Pathol*. 2004; 28:1545-1552.
5. Rouprêt M, Babjuk M, Compérat E, et al. European Association of Urology Guidelines on Upper Urinary Tract Urothelial Cell Carcinoma: 2015 update. *Eur Urol*. 2015;68(5):868-879.

E. Lymphovascular Invasion

Urothelial carcinoma may invade blood vessels or lymphatic channels. This is an important prognostic factor in upper urinary tract urothelial carcinoma.^{1,2,3} In suspicious cases, blood vessels can be highlighted by immunohistochemical staining for factor VIII-related antigen, CD31 or CD34. Staining can help resolve the problem of differentiating lymphatic versus artifactual space formation by tumor cells, a frequent finding seen in urothelial tumors invading the lamina propria. Retraction artifact is also prominent in the “micropapillary variant” of urothelial carcinoma.

References

1. Olgac S, Mazumdar M, Dalbagni G, Reuter VE. Urothelial carcinoma of the renal pelvis: a clinicopathologic study of 130 cases. *Am J Surg Pathol*. 2004; 28:1545-1552.
2. Saito K, Kawakami S, Fujii Y, et al. Lymphovascular invasion is independently associated with poor prognosis in patients with localized upper urinary tract urothelial carcinoma treated surgically. *J Urol*. 2007;178:2291-2296.
3. Kikuchi E, Margulis V, Karakiewicz PI, et al. Lymphovascular invasion predicts clinical outcomes in patients with node-negative upper tract urothelial carcinoma. *J Clin Oncol*. 2009;27(4);612-618.

F. Margins

Resection margins, including those mentioned in Note F, should be carefully specified. Statements about deep soft tissue margins should specify whether peritoneal surfaces are involved by tumor. In renal pelvis, ureter, and nephroureterectomy specimens, the margins may include radial hilar soft tissue margin; bladder cuff; and ureteral, renal parenchymal, and Gerota’s fascia margins, depending on the type of surgical specimen.

G. Lymph Nodes

Regional lymph nodes are not always submitted or identified in cases of resection,¹ but evaluation of these nodes is important. Submit one section from each grossly positive lymph node. All other lymph nodes should be entirely submitted, as presence of nodal disease may be used as an indication for

adjuvant therapy. Limited data indicate that the presence of extranodal extension may be clinically significant.

The regional lymph nodes for the renal pelvis are renal hilar, paracaval, aortic, and retroperitoneal. The regional lymph nodes for the ureter are renal hilar, iliac (common, internal [hypogastric], external), paracaval, periureteral, and pelvic.

Involvement of lymph nodes beyond the regional lymph nodes is considered distant metastasis (M1).

References

1. Olgac S, Mazumdar M, Dalbagni G, Reuter VE. Urothelial carcinoma of the renal pelvis: a clinicopathologic study of 130 cases. *Am J Surg Pathol*. 2004; 28:1545-1552.

H. Pathologic Stage Classification

The TNM Staging System for carcinomas of the ureter and renal pelvis of the American Joint Committee on Cancer (AJCC) and the International Union Against Cancer (UICC) is recommended.¹

By AJCC convention, the designation “T” refers to a primary tumor that has not been previously treated. The symbol “p” refers to the pathologic classification of the TNM, as opposed to the clinical classification, and is based on gross and microscopic examination. pT entails a resection of the primary tumor or biopsy adequate to evaluate the highest pT category, pN entails removal of nodes adequate to validate lymph node metastasis, and pM implies microscopic examination of distant lesions. Clinical classification (cTNM) is usually carried out by the referring physician before treatment during initial evaluation of the patient or when pathologic classification is not possible.

Pathologic staging is usually performed after surgical resection of the primary tumor. Pathologic staging depends on pathologic documentation of the anatomic extent of disease, whether or not the primary tumor has been completely removed. If a biopsied tumor is not resected for any reason (eg, when technically unfeasible) and if the highest T and N categories or the M1 category of the tumor can be confirmed microscopically, the criteria for pathologic classification and staging have been satisfied without total removal of the primary cancer.

Primary Tumor (T) (Figure 1)

The suffix “m” should be added to the appropriate T category to indicate multiple tumors. The suffix “is” may be added to any T to indicate the presence of associated carcinoma in situ.

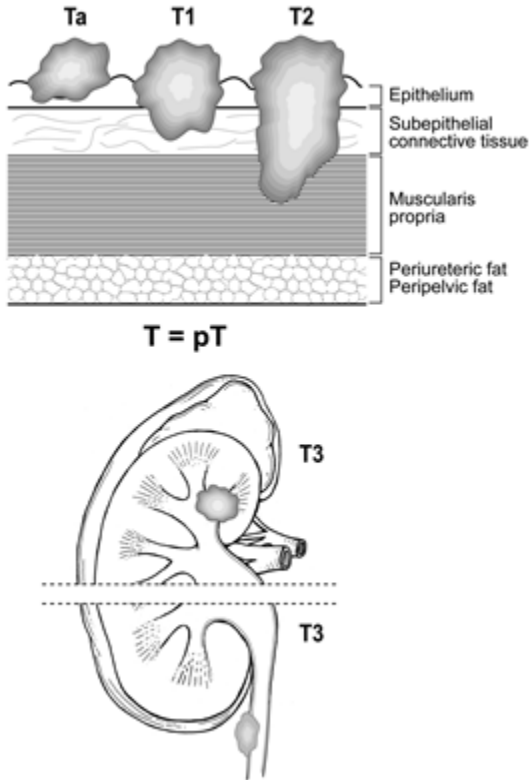


Figure 1. Depiction of pTa, pT1, pT2, and pT3.

TNM Descriptors

For identification of special cases of TNM or pTNM classifications, the “m” suffix and “y” and “r” prefixes are used. Although they do not affect the stage grouping, they indicate cases needing separate analysis.

The “m” suffix indicates the presence of multiple primary tumors in a single site and is recorded in parentheses: pT(m)NM.

The “y” prefix indicates those cases in which classification is performed during or following initial multimodality therapy (ie, neoadjuvant chemotherapy, radiation therapy, or both chemotherapy and radiation therapy). The cTNM or pTNM category is identified by a “y” prefix. The ycTNM or ypTNM categorizes the extent of tumor actually present at the time of that examination. The “y” categorization is not an estimate of tumor prior to multimodality therapy (ie, before initiation of neoadjuvant therapy).

The “r” prefix indicates a recurrent tumor when staged after a documented disease-free interval and is identified by the “r” prefix: rTNM.

References

1. Amin MB, Edge SB, Greene FL, et al., eds. *AJCC Cancer Staging Manual*. 8th ed. New York, NY: Springer; 2017.

I. Pathologic Findings in Nonneoplastic Kidney

It is important to recognize that medical kidney diseases may be present in nonneoplastic renal tissue in nephrectomy and nephroureterectomy specimens.^{1,2} Arterionephrosclerosis (or hypertensive nephropathy) and diabetic nephropathy are seen in approximately 30% and 20% of cases, respectively. Other medical renal diseases that have been identified include thrombotic microangiopathy, focal segmental glomerulosclerosis, and IgA nephropathy. The findings of greater than 20% global glomerulosclerosis or advanced diffuse diabetic glomerulosclerosis are predictive of significant decline in renal function 6 months after radical nephrectomy.² Evaluation for medical renal disease should be performed in each case; PAS and/or Jones methenamine silver stains should be applied if necessary. Consultation with a nephropathologist should be pursued as needed.

However, no studies have specifically measured peritumoral-related changes in the renal cortex. Some tumors have no peritumoral changes. Oncocytoma is the best example. While some large tumors often have a large zone of peritumoral changes compared with smaller tumors. The pseudocapsule may contain sclerotic glomeruli, tubular atrophy and show fibrointimal thickening of arteries, followed by a zone of several millimeters of acute tubular injury, none of which is representative of the cortex elsewhere.³ A judgement whether the amount of nonneoplastic renal parenchyma is sufficient for evaluation of medical kidney diseases should be made on a case by case basis. Two studies have used 1 mm to 5 mm as the cut-off for insufficient renal parenchyma^{4,5}; 5 mm of nonneoplastic renal parenchyma is a reasonable recommendation.

References

1. Henriksen KJ, Meehan SM, Chang A. Nonneoplastic renal diseases are often unrecognized in adult tumor nephrectomy specimens: a review of 246 cases. *Am J Surg Pathol.* 2007;31:1703-1708.
2. Bijol V, Mendez GP, Hurwitz S, Rennke HG, Nose V. Evaluation of the nonneoplastic pathology in tumor nephrectomy specimens: predicting the risk of progressive failure. *Am J Surg Pathol.* 2006;30:575-584.
3. Bonsib SM, Pei Y. The non-neoplastic kidney in tumor nephrectomy specimens: what can it show and what is important? *Adv Annt Pathol.* 2010;17(4):235-250.
4. Garcia-Roig M, Gorin MA, Parra-Herran C, et al. Pathologic evaluation of non-neoplastic renal parenchyma in partial nephrectomy specimens. *World J Urol.* 2013;8(4):835-839.
5. Henriksen KJ, Meehan SM, Chamng A. Nonneoplastic kidney diseases in adult tumor nephrectomy and nephroureterectomy specimens: common, harmful, yet underappreciated. *Arch Pathol Lab Med.* 2009;133(7):1012-1025.